

Lumbrical Muscle Tear - Clinical Presentation, Imaging Findings and Outcome.

Christoph Lutter^{1,2,*}, Andreas Schweizer³, Thilo Hotfiel⁴, Volker Schöffl^{1,5,6}, Isabelle Schöffl¹, Michael Simon¹, Raphael Heiß⁷, Frank Römer⁷, Thomas Bayer⁷

¹Dept. of Sports Orthopaedics, Sports Medicine, Sports Traumatology, Klinikum Bamberg, Germany

²CVPath Institute, Gaithersburg, USA

³Hand Surgery Department, Balgrist University Hospital, University of Zurich, Zurich, Switzerland

⁴Dept. of Orthopedics, Friedrich-Alexander University Erlangen-Nuremberg, Germany

⁵Dept. of Trauma and Orthopaedic Surgery, Friedrich Alexander University Erlangen-Nuremberg, Germany

⁶Department of Emergency Medicine, Section Wilderness Medicine, University of Colorado, Denver

⁷Dept. of Radiology, Friedrich Alexander University Erlangen-Nuremberg, Germany

*Corresponding author: christoph.lutter@googlemail.com

Abstract:

Injuries of the lumbrical muscles have rarely been described in the past but are currently rapidly increasing due to changing sporty preferences (e.g. climbing). We now aimed to retrospectively study imaging findings, clinical presentations and outcomes of patients with lumbrical muscle injuries treated according a standardized diagnostic and therapeutic algorithm.

Clinical data and imaging findings of 60 patients suffering from an acute lumbrical muscle strain trauma in the middle hand were retrospectively reviewed. Clinical examination, magnetic resonance imaging (MRI) and ultrasound (US) were performed before and after treatment. Lumbrical muscle injuries were graded according to the severity of clinical and imaging findings as grade I-III injuries. The therapy consisted of immobilization, functional therapy and adapted sport activities according to injury grade.

Clinical testing with shear stress examination of the flexor tendons was positive in all patients. Grade II injuries with partial tears of the lumbrical muscles were detected in 32/60 patients (Grade II). Positive imaging correlation with complete detachment of the lumbrical muscle from the flexor tendons was present in 10/60 patients (Grade III). Follow up US and MRI showed injury healing in all patients. All patients had an uncomplicated outcome and regained full sporty activities. Lumbrical muscle tears are frequently encountered injuries in climbing sport but also appear in non-climbers. Overall outcome among our study collective was positive und uncomplicated, but symptoms may recur or become chronic if not treated sufficiently. Evaluation of specific clinical and imaging findings is necessary for grading the injuries and determination of therapy.

Key Words: Lumbrical muscle injury, tendon, hand

Résumé/concept

Déchirure musculaire du lombrical-Présentation clinique, résultats par imagerie et résultat final.

Les lésions des muscles lombricaux ont été peu décrites par le passé, mais à présent, elles sont en nombre croissant à cause de performances sportives qui changent parce que les temps changent. Parmi ces performances on peut citer l'escalade sportive.

Nous sommes en mesure de reconsidérer des études d'imagerie, des présentations cliniques ainsi que des résultats chez des patients ayant subi des lésions de muscles lombricaux traités selon un diagnostic standard et un algorithme thérapeutique.

On a repris les données cliniques et les résultats d'imagerie de 60 patients ayant subi un traumatisme sévère du muscle lombrical de la main médiane. Examens cliniques, imagerie par résonance magnétique (IRM) et ultrasons (US) ont été effectués avant et après le traitement. Les lésions du muscle lombrical ont été classées selon les résultats des examens cliniques et les résultats d'imagerie sur une échelle de I à III. La thérapie consistait à l'immobilisation, thérapie fonctionnelle et activités sportives variant selon la gravité des blessures.

Un test clinique avec examen de contrainte des tendons fléchisseurs était positif chez tous les patients. On a détecté des lésions de degré II avec des déchirures partielles des muscles lombricaux chez 32 des 60 patients. Une corrélation d'imagerie positive avec un détachement complet du muscle lombrical des tendons fléchisseurs a été constaté chez 10 des 60 patients (degré III). Des ultrasons ultérieurs et un IRM ont montré des processus de cicatrisation chez tous les patients. Leur rétablissement s'est effectué sans complication et ils ont pu reprendre leurs activités sportives. On observe souvent des déchirures du muscle lombrical dans les sports de grimpe mais on les observe aussi chez des non-grimpeurs.

Le résultat global dans notre étude a été très satisfaisant et sans complication notable, mais certains symptômes peuvent être récurrents et devenir chroniques s'ils ne sont pas traités correctement. Une évaluation des résultats d'imagerie et des résultats cliniques est nécessaire pour déterminer le degré de gravité des lésions afin de décider de la thérapie à suivre.

Mots-clés: lésion du muscle lombrical, tendon, main

Short Summary of the Manuscript:

Lumbrical muscle tears are rare injuries of the palm caused by a so-called “quadriga effect”, which describes a shear injury resulting from pathologic stress to the two origins of the bipennate lumbrical muscle (Schweizer, 2003; Verdan and Poulencas, 1975). The purpose of this study was to retrospectively analyse data from 60 consecutive patients with lumbrical muscle tears with respect to clinical presentation, imaging findings, therapy and outcomes.

Materials and methods

Patients: Between 2009 and 2017, we investigated 60 consecutive patients suffering from pain in the palm provoked by a shift of the deep flexor tendons of the adjacent fingers (Table 1), which reflects the “quadriga effect” (Figure 1). Diagnostic Algorithm: A grading system was developed based on the assessment of patients not included in the current study sample, according to the severity of clinical and imaging findings (Figure 2).

Therapeutic Algorithm: All patients were treated conservatively according to the algorithm shown below (Figure 2). Outcome: All patients were seen for follow-up investigations 6 and 12 weeks after the initial consultation. Complete healing was defined as when patients were fully free of symptoms at follow-up.

Results

Incidence of quadriga effect: All 60 patients reported onset of pain after excessive loading of isolated ring or middle fingers according to the quadriga effect described by Schweizer (2003), without evidence of other causes, such as inflammatory factors or tumour (Table 1). Locations of injuries in ultrasound images and MRI: US located the injuries in the fourth lumbrical muscle in 23 of the 32 grade II cases and in the third lumbrical muscle in nine. MRI located musculotendinous disruption in the fourth lumbrical muscle in eight of the 10 of the grade III cases and in the third lumbrical muscle in two. The average length of lumbrical muscle discontinuity was 1.1 (0.2) millimetres. **Outcomes:** The recovery and outcomes of patients in injury subgroups are given in table 1. All patients were free of pain after 12 weeks of conservative treatment. Statistical analysis revealed no significant differences between the three sub-groups, except that the healing period for the Grade III injuries was significantly longer than in the two other sub-groups ($P < 0.001$).

Discussion

Our study confirms that symptoms from lumbrical muscle tears resolve after conservative therapy. Recovery takes longer in more severe injuries where there is musculotendinous discontinuity. The suggested pathomechanism of motion of the fingers, referred to as “quadriga effect” (Schweizer, 2003; Verdan and Poulernas, 1975), was noted in all cases. There was no association of injury severity with patient age, gender or hand dominance. However, more severe injuries occurred in patients who climbed on a higher performance level. It is noteworthy that conservative therapy was successful even in the Grade III sub-group in which MRI showed a musculotendinous disruption. This is most likely explained by the limited distances of tendon separation in the lumbrical origin and the fact that no wavelike retracted tendon configurations were present. Musculotendinous disruption as found in the Grade III tears is an imaging finding which has not been described in previous studies. We consider this finding as therapeutically relevant with temporary immobilisation being required. This policy was supported by the longer time to full recovery for these injuries compared with Grade II and I injuries. Our study confirmed the so-called “theta sign”, as described by Wang et al (Wang et al., 2016), which refers to a reactive tenosynovitis resembling the Greek letter θ (theta), surrounding the flexor tendons of the affected finger in 50% of the patients. Beyond that, our imaging revealed a great variety of location and extent of muscle oedema, tenosynovitis and/or localization of the lumbrical muscle tear.

In summary, the overall outcome in our series of lumbrical muscle tears was positive and uncomplicated using a conservative treatment strategy according to our algorithms. We recommend evaluation of specific clinical and imaging findings to grade the severity of these injuries and to determine the suitable course of therapy.

REFERENCES

- Chicarilli ZN, Watson HK, Linberg R, Sasaki G. Saddle deformity. Posttraumatic interosseous-lumbrical adhesions: Review of eighty-seven cases. *J Hand Surg Am.* 1986, 11: 210-8.
- Drape JL, Tardif-Chastenot de Gery S, Silbermann-Hoffman O et al. Closed ruptures of the flexor digitorum tendons: MRI evaluation. *Skeletal Radiol.* 1998, 27: 617-24.
- Lapegue F, Andre A, Brun C et al. Traumatic flexor tendon injuries. *Diagn Interv Imaging.* 2015, 96: 1279-92.
- Liss FE. The interosseous muscles: The foundation of hand function. *Hand Clin.* 2012, 28: 9-12.
- Murphy RX, Jr, Chernofsky MA. Tear of an anomalous lumbrical muscle as a source of pain in the hand. *J Hand Surg Am.* 1999, 24: 1078-82.
- Palti R, Vigler M. Anatomy and function of lumbrical muscles. *Hand Clin.* 2012, 28: 13-7.
- Parminder K. Morphological study of lumbricals - a cadaveric study. *J Clin Diagn Res.* 2013, 7: 1558-60.
- Schöffl V, Heid A, Kupper T. Tendon injuries of the hand. *World J Orthop.* 2012, 3: 62-9.

- Schöffl V, Popp D, Küpper T, Schöffl I. Injury trends in rock climbers: Evaluation of a case series of 911 injuries between 2009 and 2012. *Wilderness Environ Med.* 2015, 26: 62-7.
- Schöffl V, Willauschus W, Sauer F et al. Autologous conditioned plasma versus placebo injection therapy in lateral epicondylitis of the elbow: A double blind, randomized study. *Sportverletz Sportschaden.* 2017, 31: 31-6.
- Schöffl VR, Schöffl I. Finger pain in rock climbers: Reaching the right differential diagnosis and therapy. *J Sports Med Phys Fitness.* 2007, 47: 70-8.
- Schweizer A. Lumbrical tears in rock climbers. *J Hand Surg Br.* 2003, 28: 187-9.
- Tan V, Rothenfluh DA, Beredjiklian PK, Potter HG, Weiland AJ. Interosseous-lumbrical adhesions of the hand: contribution of magnetic resonance imaging to diagnosis and treatment planning. *J Hand Surg Am.* 2002, 27: 639-43.
- Verdan C, Poulenas I. Anatomic and functional relations between the tendons of the long palmar muscle and the long flexor muscle of the thumb at their crossing in the carpus. *Ann Chir Plast.* 1975, 20: 191-6.
- Wang EH, Loftus WK, Bird SJ, Sampson MJ. Ring finger lumbrical origin strain: A case series with imaging findings. *Skeletal Radiol.* 2016, 45: 1729-34.

Figure 1. (A) Normal anatomy of the four lumbrical muscles (I/II unipennate, III/IV bipennate) and (B) pathomechanism of lumbrical muscle tears referred to as “quadriga effect”.

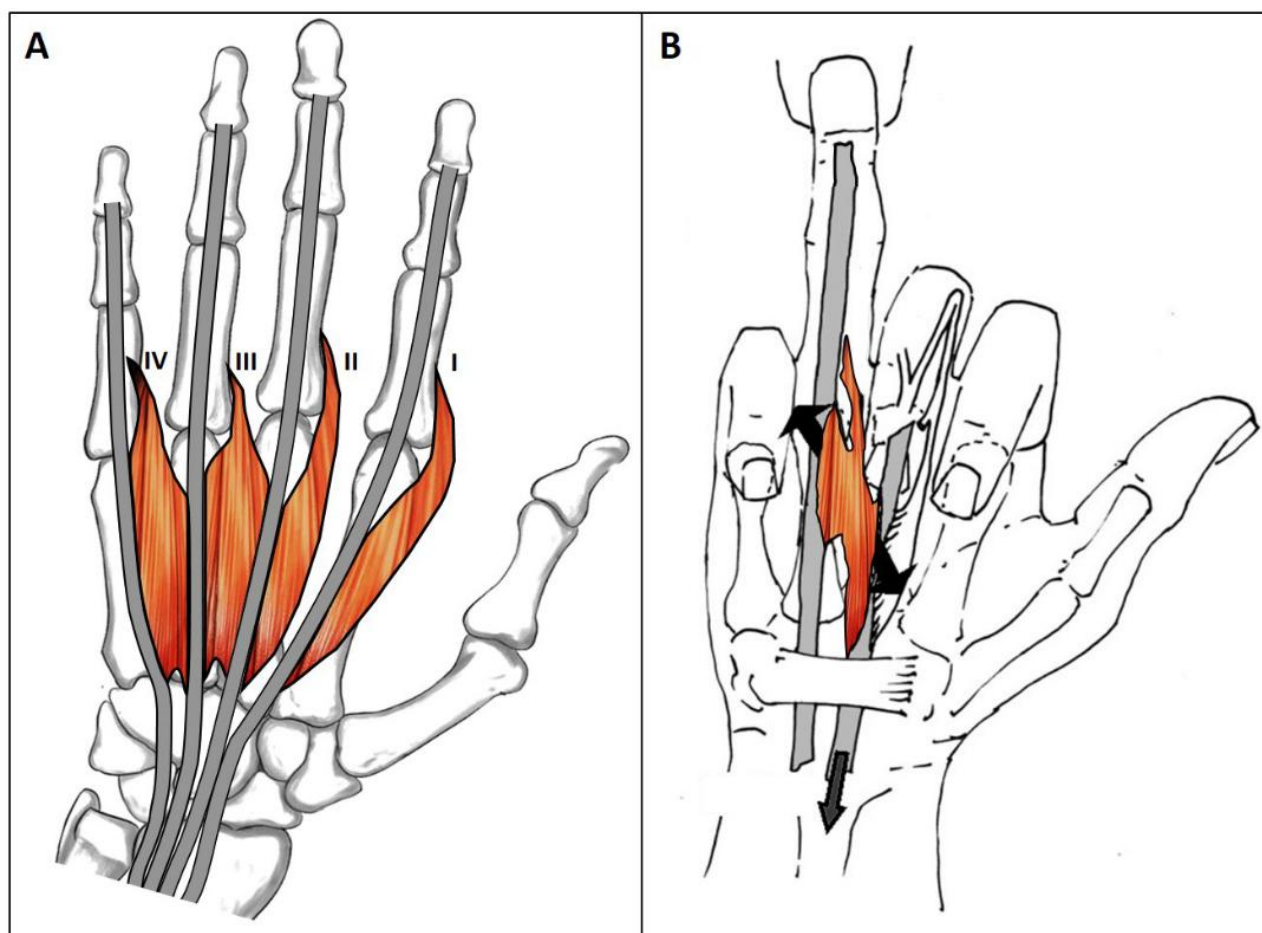


Figure 2. Algorithm of diagnostic and therapeutic treatment for lumbrical muscle injuries based on the severity of clinical and imaging findings.

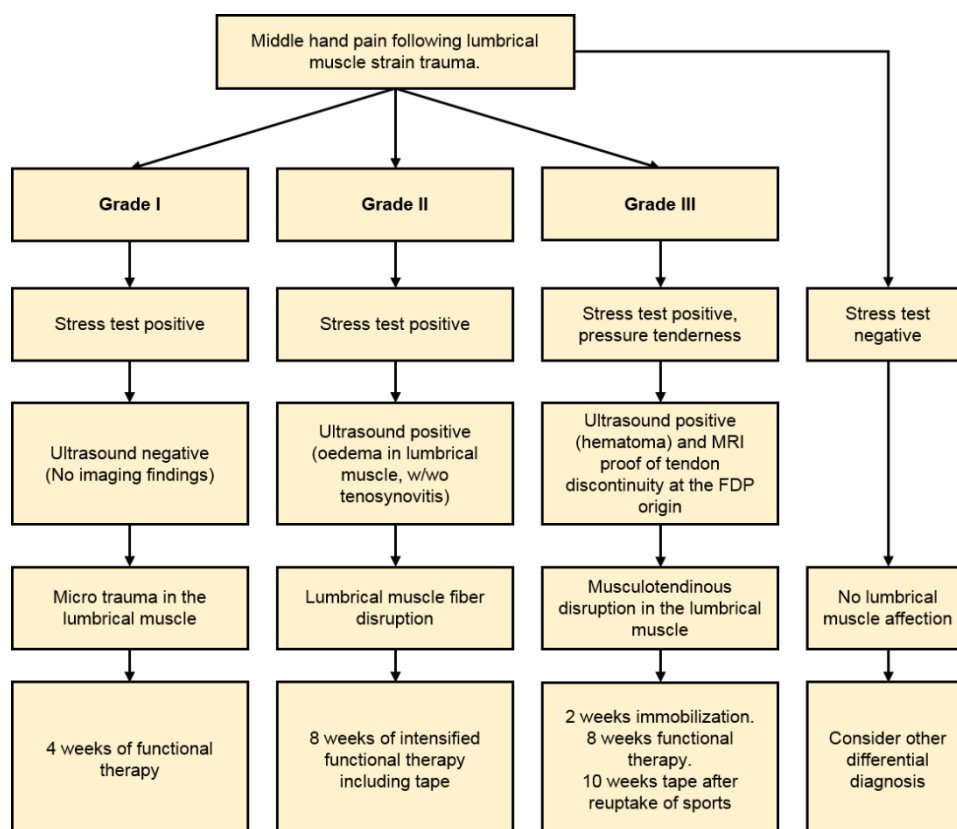


Table 1

Demographics and recovery	Overall	Grade I	Grade II	Grade III
Number of patients	60*	18 (30%)	32 (53%)	10* (17%)
Age (years)	30.3 (7.7) (range 18.0 – 46.5)	30.3 (7.7) (range 19.0 – 46)	29.5 (7.6) (range 18 – 45)	32.7 (8.7) (range 23 – 45)
Sex (men:women)	45:15	14:4	26:6	5:5
Acute/Chronic presentation	57/3	18/0	29/3	10/0
Affected side (R:L)	32:28	8:10	21:11	3:7
Handedness (R:L)	53:7	16:2	28:4	9:1
Affected finger (middle:ring)	16:44	5:13	9:23	2: 8
Healing period (weeks)	7 (2) (range 3 - 12)	5 (1) (range 4 - 8)	6 (2) (range 3 - 9)	10 (2) (range 8 - 12)
UIAA** Climbing level (among climbers)	8.8 (1.1)	8.4 (0.7)	8.9 (1.2)	9.7 (0.8)

*Three patients in these categories are non-climbers

** Scale ranging from 2 to 11 (Union Internationale des Associations d'Alpinisme (UIAA), www.theuiaa.org)